

# The Ice Hockey Injury



## *A Case Study in Physiology*



**Phil Stephens**  
Biology Department  
Villanova University, Villanova, PA

National Center for Case Study Teaching in Science



## Part I—The Big Game

“That’s the problem with being the star player on any team, Rick, you’ve got a target on your shirt,” the coach said as his first line center skated slowly off the ice.

The coach knew that varsity ice hockey was rough, but now he was thinking about the wisdom of traveling so far across country for this tournament in the middle of nowhere. There were only a few minutes left in this third and final game of the day. His players were tired. The teams were evenly matched, but loose officiating in the last period made the coach worry that his team’s injury list would grow. The kids were showing heart, all playing with bumps and bruises, but the hitting was intensifying and it seemed to him that the opposition was going after his better players.

“Change it up!”

The first line went back out and the coaches watched as Rick took the ice and the opposition’s checking line went with them.

“Okay, guys, we’re shortening the shifts, so keep your heads up and don’t get caught on the boards.”

Just at that moment one of the wings came off after a collision, and Rick was collecting the bouncing puck behind his own net. The opposition took advantage of the extra man to double team Rick.

“Was that an elbow or his stick?” asked the coach as Rick slammed against the boards.

Rick crumpled to the ice, doubled over in pain. The whistles blew. The coaches slid their way out to Rick, who was still lying curled on the ice.

“Great,” said the assistant coach. “A one-man advantage with less than two minutes remaining, and our best player is out of the game, perhaps even out of the tournament.”

Blood was dripping from Rick’s mouth and his eyes were glazed over. A parent started onto the ice, and the assistant coach told the referee that the man was a doctor.

“Can you get him off the ice so we can finish the game?” asked an official.

The coaches looked at the doctor, who nodded, and the two coaches lifted Rick to his feet, almost carrying him to the bench.

“Okay guys, pull the goalie. Two man advantage. Let’s put them away.”

The bench buzzed with excitement at the risky move, but the coach turned his back on the game and attended to Rick, who was slumped in a corner of the bench.

“Ready to go on, coach,” Rick muttered.

The coach smiled. “What happened, Rick?”

“One guy stood me up and the other hit me in the gut with the butt end of his stick. Here, just below my ribs.”

The doctor lifted Rick’s shirt and could see the bruise beginning to form around his diaphragm on the left side.

“I think a trip to the local emergency room may be in order,” said the doctor.

“Don’t worry, Dad, I’ve had worse,” but Rick’s words were lost in cheers as the team scored with a few seconds to go. The horn sounded and Rick sprang to his feet, blood still dripping from his mouth, and rushed onto the ice to celebrate with his team.

“Nothing much wrong with him,” said the coach.

### *Questions*

1. What organs are located on the left side in the vicinity of the diaphragm?
2. What symptoms does Rick exhibit?
3. What are the possible diagnoses for Rick’s condition at this time? For each diagnosis that you come up with, describe the symptoms that relate to that diagnosis.
4. Was the coach right in his assessment of Rick’s condition?



## Part II—That Evening

Each member of the triumphant team entered the hotel carrying his oversized bag in one hand and a water bottle in the other.

“Okay, guys, get your keys, get showered and dressed, and we’ll meet down here in 45 minutes—that’s 8 o’clock. A deal’s a deal. You guys won all three games, so the all-you-can-eat restaurant is going to see some serious damage tonight. In the meantime, drink lots of water to keep yourselves hydrated.”

The players were in a good mood, but Rick was quiet. Andrew, his roommate for away games since sixth grade, noticed Rick wasn’t his usual self.

“You okay, Rick?”

“Just a little tired. You go first. I’m going to lie down.”

Andrew thought this was peculiar because they usually fought for the first shower. Rick was a neat freak. He would never lie on his bed after a game without showering. And he was usually full of energy, always joking, and boy could he eat. Maybe he would be okay after he got some food in him.

“Hey, Rick, you still alive? Shower’s yours,” said Andrew, coming out of the bathroom.

Rick was lying on his bed watching TV. Taking the hint, Rick stood up, but then immediately sat back down.

“Wow, got up a bit too quickly on that one,” he said as he slowly pulled himself back to his feet, collected some clothes, and went into the bathroom.

“All set?” asked Andrew as Rick walked out of the bathroom 10 minutes later.

“Good to get that taste of dried blood out of my mouth.”

“I think the coach may want you to put on a shirt instead of those old sweats, since we’re representing the school,” said Andrew.

“I don’t feel all that great. I think I’ll just stay here and watch the end of this movie. Can you bring me back some food from the restaurant?”

Andrew looked at Rick. Something was definitely wrong. No sooner had Andrew left than the coach and Rick’s father were in his room.

“I’m okay, I just feel a little fuzzy. Maybe I’ve got Jen’s virus or maybe three games in one day was just too much after playing that soccer game yesterday afternoon.”

Rick’s father did his “doctor bit,” as Rick called it. His son looked a little pale and tired, but there was no fever and his pulse seemed normal.

“You have been overdoing things lately, Rick, maybe you just need to rest. We’ll check in with you when we return. Keep your cell phone on and call if you feel worse.”

“Okay, Dad. Can you fill my water bottle and this glass before you go?”

### *Questions*

1. What new symptoms does Rick exhibit?
2. Why does Rick feel sick?
3. Why is Rick drinking so much water at this time?
4. Do you wish to modify your list of possible diagnoses at this time? What new information did you use to modify that list?



## Part III—After Dinner

You could hear the hockey team coming down the corridor. That was quick, Rick thought, but then saw that two hours had passed. He felt thirsty and reached for his glass. It was empty and so was the big water bottle. The door opened.

“Just in time. Get me some water, will you.”

Andrew smiled, took the glass and leaned into the corridor to call for the coach.

“Do you feel as bad as you look?” asked the coach as he came in the door.

“I feel okay, why?” asked Rick.

“I don’t think I have ever seen anyone look gray before,” said Andrew.

“Don’t give me a hard time, Andy. Maybe I look so bad because you woke me from a deep sleep. Wait until we get on the ice tomorrow, I’ll show you. That soccer game today was nothing.”

“That was yesterday, Rick. That hit has made you confused and delirious,” Andy laughed.

Rick looked confused and started to cough. He stood up and reached for the glass of water. Suddenly his eyes rolled back in his head, his knees buckled, and he slumped over on the bed. As Rick regained consciousness, he coughed and winced from the sharp pain in his left side. He clumsily rolled onto the bed gasping for air. His breathing was fast, heavy and labored, and he could feel his pulse pounding in his temples.

Rick’s father felt his pulse.

“His heart is racing. We need to get him to a hospital, now. I’ll get my car. Andy, get a couple of the guys and carry Rick down to the lobby. I’ll meet you out front. Coach, can you get directions to the local hospital?”

The room was a flurry of activity. In less than 10 minutes the four of them were in the emergency room of the local hospital. When Rick’s father told the attendant that he was a physician, they were immediately admitted and the ER doctor appeared.

“Hi, I’m Dr. Paul Anderson. Someone told me we have a wounded hockey player here. Oh, I know you. You’re the one who took the big hit at the end of the game this evening. It looked pretty bad. I’m surprised you got up. My son was playing on the other team.”

### *Questions*

1. What new symptoms does Rick exhibit?
2. Why did Rick faint when he stood up?
3. Can fainting be linked to any other of his symptoms?
4. Why is Rick’s pulse racing?
5. Was Rick’s father correct to take him to the hospital?
6. Do you wish to modify your list of possible diagnoses at this time? What new information did you use to modify that list?
7. If you were an ER physician, what tests would you perform to help narrow the possible diagnoses for Rick’s condition?



## Part IV—The Emergency Room

Having his doctor here has made my life easier,” said the ER physician. “It allows us to compare Rick’s present condition to his normal one. To help things along, I have written down the results of some of the tests we have completed so far. The chest x-ray will be here soon, but in the meantime let’s see what we can see.”

<i>Test</i>	<i>Rick</i>	<i>Normal</i>
<i>ECG</i>	<i>Normal (fast)</i>	<i>Normal</i>
<i>Heart Rate (b/m)</i>	<i>105</i>	<i>65</i>
<i>Blood Pressure</i>	<i>85/55</i>	<i>110/65</i>
<i>PO<sub>2</sub></i>	<i>78</i>	<i>100</i>
<i>PCO<sub>2</sub></i>	<i>55</i>	<i>40</i>
<i>Blood pH</i>	<i>7.1</i>	<i>7.4</i>
<i>Hematocrit</i>	<i>48</i>	<i>45</i>
<i>Blood volume (L)</i>	<i>3.2</i>	<i>5.1</i>

*Abdomen: no swelling; upper left quadrant: pain, bruised, tender.*

*Respiration: rapid, deep; labored breathing; cough.*

*Urine: none available; patient has NOT urinated in last (+) 6 hours*

### **Questions**

1. Do these results correlate with your initial diagnosis?
- 2 Why is Rick’s blood volume low?
3. Where did the blood go? Do you think that Rick could have lost so much blood from his cut mouth?
4. Do you wish to modify your list of possible diagnoses at this time? What new information did you use to modify that list?



## Part V—The CAT Scan

“Rick’s CAT scans are ready.” They all looked at the monitor.

Figure 1—Upper GI

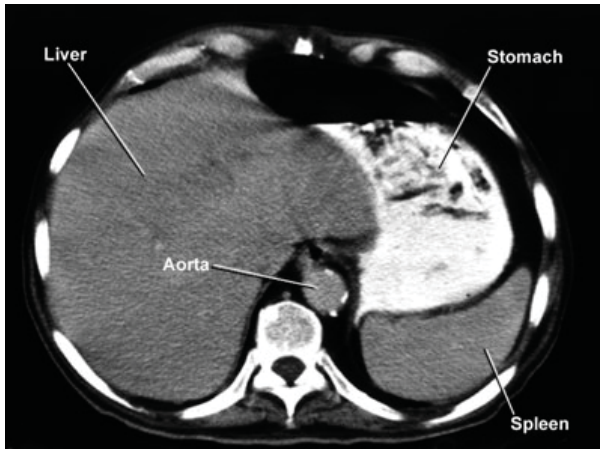
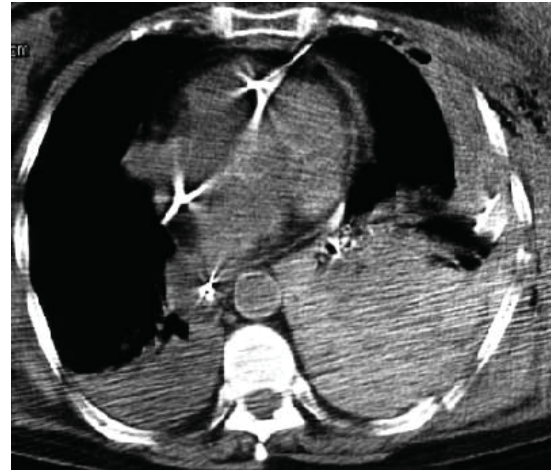


Figure 2—Chest



### Questions

1. What does Rick’s CAT scan of his upper GI indicate about his condition?
2. What does Rick’s CAT scan of his chest indicate about his condition?
3. Do you wish to modify your list of possible diagnoses at this time? What new information did you use to modify that list?
4. Check the data table and confirm that each entry is consistent with your diagnosis.

### Image Credits

Figure 1—Used with permission of the Division of Anatomical Education, Department of Neurobiology and Developmental Sciences, University of Arkansas for Medical Sciences.

Figure 2—Reprinted from Kuhlman JE, et al. Radiographic and CT findings of Blunt Chest Trauma: Aortic Injuries and Looking Beyond Them. *RadioGraphics* 1998;18:1085–1106. Fig. 22. Used with permission of the authors and the Radiographic Society of North America.



## Part VI—The X-Ray

A nurse entered the ER with an envelope. “Dr. Anderson, here is the x-ray you asked for.”

The ER physician pulled the x-ray out of the envelope and jammed it into the light box.

“Now, let’s see what’s going on. Coach, Andy, I’ve put a normal x-ray over here so that you can compare it with Rick’s.”

“It’s at a slightly different angle, but Rick’s chest x-ray doesn’t look normal to me,” said Andy.

Figure 3—Normal

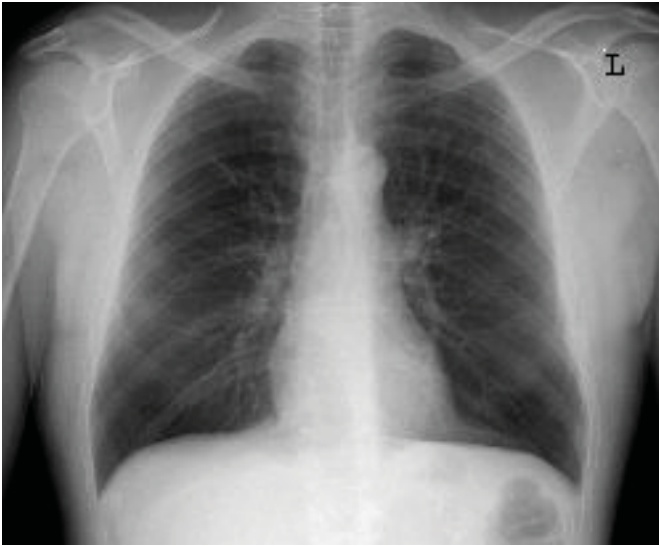
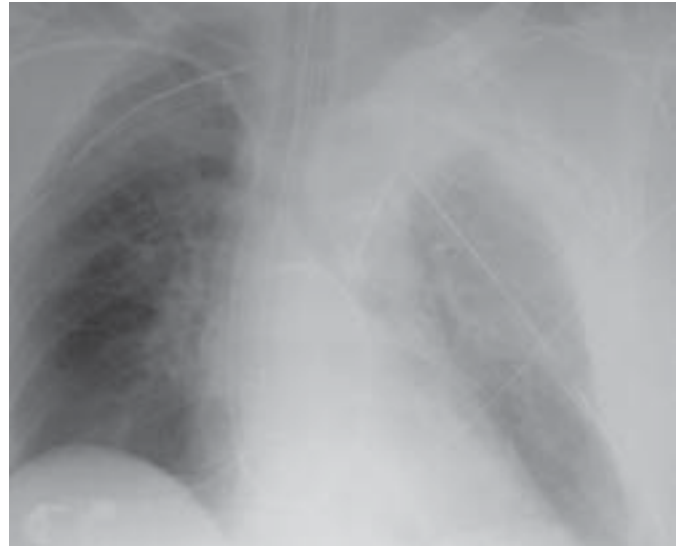
Figure 4—Rick



### Questions

1. What does Rick’s x-ray indicate about his condition?
2. Do you wish to modify your list of possible diagnoses at this time? What new information did you use to modify that list?
3. Check the data table and confirm that each entry is consistent with your diagnosis.

### Image Credits

Figure 3—Courtesy of US FDA.

Figure 4—Reprinted from Kuhlman, J.E., et al. Radiographic and CT findings of Blunt Chest Trauma: Aortic Injuries and Looking Beyond Them. *RadioGraphics* 1998;18:1085–1106. Fig. 22. Used with permission of the authors and the Radiographic Society of North America.





## Part VII—Final Questions

### *Questions*

1. What is the mechanism whereby Rick's lung collapsed?
2. What are the two main problems facing the ER physician?
3. What would be your short-term and long-term treatments for the problem in the x-ray?
4. Rick was very thirsty after the game and drank a great deal of water that evening. Can you describe the reasons why Rick was so thirsty? Relate each answer to Rick's symptoms.
5. What would be your short-term and long-term treatments for the blood volume problem?

Case copyright held by the [National Center for Case Study Teaching in Science](#), University at Buffalo, State University of New York. Originally published April 19, 2004; last revised October 21, 2004. Please see our [usage guidelines](#), which outline our policy concerning permissible reproduction of this work.